



## Fusobacterium Necrophorum

### What is it?

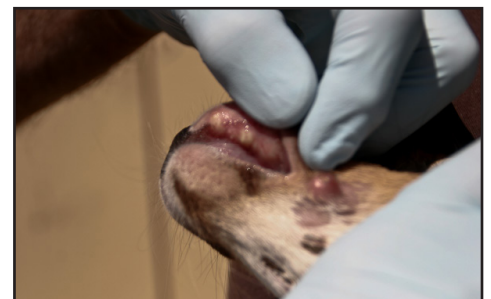
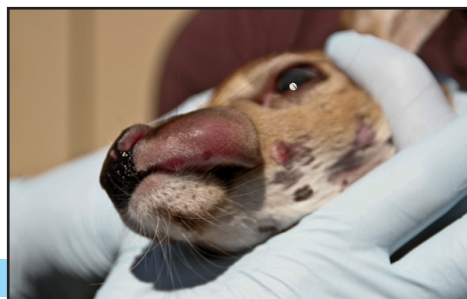
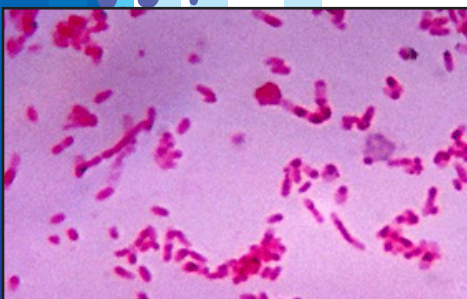
- “Anaerobic” gram negative bacteria. Anaerobic simply means it likes to grow in places with little oxygen.
- Causes Necrobacillosis, the definition of necrobacillosis is any disease marked by necrotic (death of cell tissue) areas in which bacillus (rod shaped or cylindrical bacterium) is found.

### What symptoms are typically seen in Cervid?

- Trench Mouth (commonly referred to as Lumpy Jaw)
- Foot rot
- Respiratory problems, Pneumonia
- Abscesses
- In rare cases it can be found in Uterine Infections and Mastitis

### How is it spread?

- The organisms gain entry into the body through cuts and abrasions to the skin or mucous membranes. In the mouth many outside influences could cause abrasions, such as coarse feed or metal objects along with unevenly worn or new erupting teeth which can penetrate or damage the oral lining and create points of entry. Fusobacterium survives well in wet soil and when mouth abrasions make contact with contaminated soil it can result in infection. Overcrowding and stress can propagate diseases caused by this bacterium.
- Changes in the rumen environment, such as grain overload or sudden changes in feed can damage the stomach lining and provide a portal of entry for Fusobacterium where bacteria may pass to the liver causing hepatic necrobacillosis (death of liver tissue), or move on to other organs.
- Fusobacterium is transmissible through contaminated feed or water troughs from an infected animal
- Fusobacterium minimally affects more than one deer at a time but can affect several fawns
- With the case of foot rot injury to the interdigital skin provides a portal of entry for infection. Foot rot is also transmissible to healthy animals; it requires a warm, moist environment. Under these conditions, the interdigital stratum corneum becomes macerated (moist softened tissue in a state of deterioration); filaments of F. necrophorum invade the superficial epidermis and induce interdigital dermatitis.



## Geography

- *F. necrophorum* occurs throughout the world
- New Zealand and North American deer farms suffer significant losses from foot rot and necrotic stomatitis (tongue and throat abscesses) from the diseases

## Signs and Symptoms

### Lumpy Jaw

- Lumpy jaw also appears as a swollen jaw or cheek. It is the result of an infection of the jawbone. These lumps are immovable hard swellings of the bones, usually at the level of the central molar teeth. The swellings develop slowly and may take months to reach the size of a golf ball. They consist of honeycombed masses of bone filled with yellow pus that comprise the lumpy jaw. The swellings may become very large and discharge small amounts of sticky pus containing gritty yellow granules.

### Foot rot

- Lameness is seen when the feet and associated joints are involved. Swelling between the toes is the first sign seen, followed by localized tissue death, spreading to the joints and bones in more advanced cases. In general pain, severe lameness, fever, anorexia, loss of condition and reduced milk production can be major signs of the disease.

### Respiratory Problems, Pneumonia

- In the throat, necrotic laryngitis will show itself as loud wheezing. Some dead tissue and bacteria may be sucked into the lungs causing abscess formation and pneumonia.

### Uterine Infections

- There is a lack of research on uterine infections in the cervid community, but in a study of small flocks of sheep in Denmark, 4 of 24 ewes were found to have aborted from *F. necrophorum*. There was necrosis of the cotyledons of the placenta, which is where the maternal fetal exchange takes place.
- *F. necrophorum* can also cause metritis (inflammation of the uterine wall) and endometritis (inflammation of the endometrium). A fetid, watery uterine discharge is characteristic of this condition in cows but may be conspicuous in other species.

### Mastitis

- There are 4 different clinical types of mastitis but generally the signs are swelling, heat, pain and abnormal secretion in the gland, accompanied by fever and other signs of a systemic disturbance such as marked depression, rapid weak pulse, sunken eyes, weakness, and complete anorexia.

## Disease Management

- Proper management is important to minimize disease and reduce the contagiousness of the bacteria. Keeping deer in a clean, minimal stress environment and not overcrowding them will decrease the spread of the disease. Stress such as heat, cold, overcrowding or poor nutrition predispose to infection.
- According to the USDA approximately 1/3 of all deer and elk operations vaccinate against fusobacterium. Only 17.8% of deer operations vaccinate against *F. necrophorum*.
- Autogenous vaccines are an option in the prevention of these bacteria.

## Statistics

- In a study from 2003 on mortality rates of captive PA deer, bronchopneumonia was the most common cause of death. The majority of cases (64.1%) of bronchopneumonia occurred in deer 2 years of age or less with 46.2% of the cases seen in animals 1 year or less. *F. necrophorum* was one of the most commonly isolated bacterial respiratory pathogens from the affected lungs, accounting for 27.8% of the cases of bronchopneumonia.

### Points to Remember

- Mostly seen as Trench Mouth, Foot Rot and Pneumonia
- Fusobacterium
  - can gain entry to the body through cuts or abrasions to the skin
  - can enter through the lining of the stomach if there is abrupt change in the rumen environment
  - is transmissible through contaminated feed or water
  - can be passed from animal to animal as foot rot
- Vaccination is key to prevention, PV3 covers Fusobacterium Necrophorum

